



Erdheim-Chester disease – A case report

Oboljenje Erdhajn-Čester

Stanko Petrović*, Radoje Doder*[†], Nenad Perišić*, Marijana Petrović[‡],
Irina Brčerević*, Branka Roganović*[†]

Military Medical Academy, *Clinic of Gastroenterology and Hepatology; [‡]Clinic of
Nephrology, Belgrade, Serbia; University of Defence, [†]Faculty of Medicine of the
Military Medical Academy, Belgrade, Serbia

Abstract

Introduction. Erdheim-Chester disease (ECD) is a rare non-Langerhans-cell histiocytosis. About 500 cases are published so far. It is multisystemic disease characterised by bilateral symmetric long bones sclerosis. Main histopathological finding is accumulation of big foamy histiocytes, immunohistochemically positive to CD68, and negative to S-100 and CD1a. There are no guidelines that reliably identify population that requires therapy, but symptomatic ECD, organ failure and central nervous system involvement require treatment. **Case report.** We described a patient with a multisystemic form of ECD affecting long bones, the hypophysis, abdomen, and the peripheral nerves. Five years after initial symptoms ECD was suspected. Prednisone was initiated, 60 mg once a day. After obtaining the diagnosis of ECD, interferon alpha 2A was introduced, but soon after stopped due to severe side effects. Considering that histiocytes were positive to platelet derived growth factor receptor alpha (PDGFR alpha) imatinib mesylate was started, but after two months stopped due to no clinical and radiological improvement. The disease was worsening and the patient died. **Conclusion.** We described the patient with intraperitoneal form of ECD, without cardiac and pulmonary involvement. There are several important issues: the diagnosis of ECD could be difficult to make, three treatment regimens were included and the patient died nine years after the initial symptoms due to indolent course of the disease and unsuccessful treatment.

Key words:
erdheim-chester disease; diagnostic techniques and procedures; immunohistochemistry; diagnosis, differential; drug therapy.

Apstrakt

Uvod. Oboljenje Erdhajn-Čester (Erdheim-Chester, ECD) je redak oblik ne-Langerhansove histiocitoze sa oko 500 bolesnika prikazanih do sada. To je multisistemska bolest koju karakteriše bilateralna simetrična kortikalna skleroza dugih kostiju. Patohistološki, karakteriše se nakupljanjem histiocita imunohistohemijski pozitivnih na CD68 i negativnih na S-100 i CD1a. Nema jasnih preporuka za lečenje, ali bolesnici sa simptomima, disfunkcijom organa ili zahvatanjem centralnog nervnog sistema zahtevaju lečenje. **Prikaz bolesnika.** Prikazali smo bolesnika sa multisistemskim oblikom ECD, sa zahvatanjem dugih kostiju, hipofize, trbušne duplje i perifernih nerava. Pet godina posle prvih simptoma posumnjalo se da se radi o ECD. Lečenje je započeto prednisonom, 60 mg jednom dnevno. Kada je potvrđena dijagnoza ECD uveden je interferon alfa 2A, ali je ubrzo ukinut zbog neželjenih efekata. S obzirom na to da su histiociti bili pozitivni na trombocitni faktor rasta alfa (PDGFR alfa) u terapiju je uveden imatinib mesilat. Nakon dva meseca terapije, imatinib je ukinut zbog nedostatka terapijskog efekta. Zbog pogoršanja bolesti, nastupio je smrtni ishod. **Zaključak.** Prikazali smo bolesnika sa intraperitonealnom lokalizacijom bolesti, bez zahvatanja srca i pluća. Postoji nekoliko ključnih stavki: dijagnoza ECD može biti otežana, bila su uključena tri režima terapije i bolesnik je preminuo devet godina od početnih simptoma zbog sporog toka bolesti i neuspešnog lečenja.

Ključne reči:
erdheim-chesterova bolest; dijagnostičke tehnike i procedure; imunohistohemija; dijagnoza, diferencijalna; lečenje lekovima.

Introduction

Erdheim-Chester disease (ECD) is a rare non-Langerhans-cell histiocytosis of unknown etiology. Around 500 cases have

been published so far, especially in the last 10 years due to increased awareness of this disease. The disease was named after William Chester and Jakob Erdheim who first described two cases with “lipoid granulomatosis”, in 1930¹. It affects adults,

both sexes equally, rarely affects children. The pathogenesis of ECD is not known. Th1 immune response is dominant, thus suggesting it as inflammatory disease, but a recent finding of BRAF V600E mutation suggests it as a clonal disease, dependent on impaired RAS/RAF/MEK/ERK signalling². Activating mutation of NRAS gene is found in 3.7% of patients³. Pathogenic BRAF V600E mutation is found in 54% of patients⁴. The disease is characterized by extensive proliferation and accumulation of histiocytes in tissue, particularly connective and fat ones. It primarily affects long bones leading to bilateral, symmetric cortical sclerosis, sparing epiphysis. Bone lesions could be confirmed on magnetic resonance imaging (MRI), technetium-99m bone scintigraphy, ¹⁸fluoro-2-deoxy-d-glucose (¹⁸FDG) positron emission tomography/computed tomography (PET)/CT scanning, but they are often missed on plain radiographs. FDG PET/CT is also useful for extraskelatal disease and in surveillance⁵. The diagnosis of ECD relies on two criteria, proposed by Veyssier-Belot et al.⁶ and they are typical histological and skeletal findings. Almost 50% of the patients have extraskelatal manifestations, including hypophysis, orbit, heart, lungs, kidneys, retroperitoneum, central nervous system (CNS) and skin. The histology is characterized by the accumulation of big foamy histiocytes with lipid-rich eosinophilic cytoplasm. Histiocytes are immunohistochemically positive to CD68, negative to S-100 and CD1a, lacking Birbeck granules on electronic microscopy. The prognosis depends upon visceral manifestations. Approximately 50–60% of the patients die after 3 years of disease, most often due to cardiac and pulmonary involvement. Treatment regimens include: glucocorticoids, cyclophosphamide, vincristine, cladribine, methotrexate, lenalidomide, imatinib mesylate, anakinra, interferon alpha, sirolimus, infliximab, vemurafenib, canakinumab, autologous hematopoietic-stem cell transplantation, radiotherapy, and surgery^{7–33}.

Case report

A male patient, 58 years old, was diagnosed with central diabetes insipidus of unknown etiology. He was treated with substitution therapy – desmopressin (Minirin® spray). Two years after, surgical ablation of the tumor, affecting soft tissue of the right lower extremity, was done. There was neither bone infiltration, nor distant metastasis. The final histopathological finding showed dedifferentiated liposarcoma or dedifferentiated schwannoma. Following the surgery, the patient was treated with radiotherapy and chemotherapy and scheduled for follow-up. Two years later, due to nausea, abdominal pain and distension, multislice computed tomography (MSCT) of the abdomen was performed. It showed ascites and the thickened peritoneum and mesenteric structures. After that, explorative laparoscopy and biopsy of the omentum, lymph nodes and small bowel mesentery were done. The final histopathological finding confirmed *inflammatio chronica xantogranulomatosa textus adiposus*. A year later, ECD was suspected based on anamnesis, clinical features and examinations performed (increased serum markers of inflammation, plain radiography survey showing bilateral symmetric cortical sclerosis of the lower extremities sparing

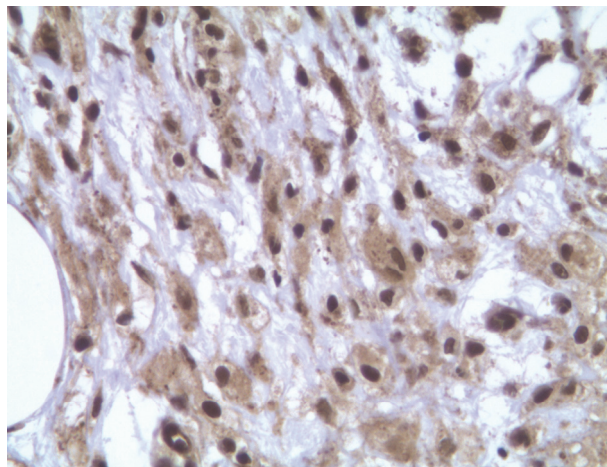
epiphysis), without cardiac and pulmonary involvement. Prednisone was started, 60 mg once a day, tapered to 15 mg once a day which he was taking for the next three years.

Due to paresthesia and weakness of the lower extremities we performed electromyoneurography (EMNG), showing sensory polyneuropathy. Alpha-lipoic acid was introduced, resulting in partial improvement. Few months later, he developed gangrene of the right lower extremity, thus above knee amputation was performed. Eight months later, we performed revision of the histopathological finding of biopsies of the peritoneum, omentum and lymph nodes, done 4 years ago, with immunohistochemical staining that confirmed the ECD (CD68+, CD1a-, S100-, CD14+, CD163+). After evaluation [upper and lower endoscopy, CT of the abdomen, bone scintigraphy, magnetic resonance imaging of the lumbosacral spine (MRLS), bone marrow biopsy, peripheral blood and bone marrow samples testing for clonal rearrangements Ig (immunoglobulin)/TCR (T cell receptor) genes, dual-energy x-ray absorptiometry], progressive disease (PD) was confirmed, along with osteoporosis as sequelae of prednisone therapy (Figures 1 and 2). Interferon alpha 2A was introduced, 3,000,000 IU 3 times weekly subcutaneously. Osteoporosis was treated with bisphosphonates. Three months later interferon alpha 2A was discontinued due to severe side effects (nausea, loss of appetite, fever, abdominal pain, diarrhea, depression), and prednisone was restarted, 20 mg once a day.

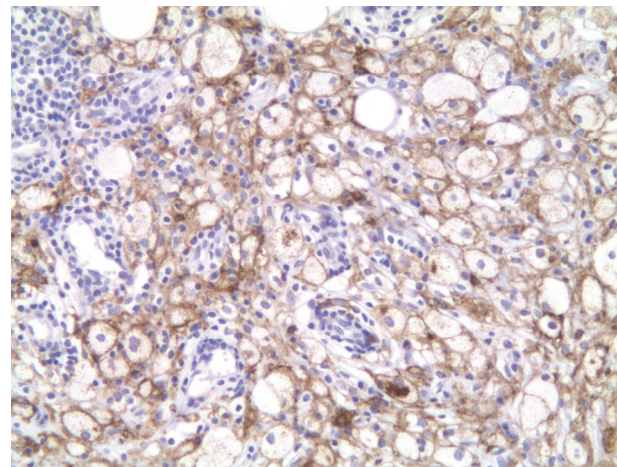
Additional immunohistochemical staining confirmed that histiocytes were positive to PDGFR alpha, so imatinib mesylate was introduced, 400 mg once a day, with tapering off prednisone till discontinuation. After two months of the treatment with imatinib mesylate there was no clinical improvement. Laboratory analysis showed increased serum markers of inflammation, low albumin (21 g/L), so imatinib mesylate was discontinued and prednisone restarted, 20 mg once a day. The introduction of prednisone led to a short-term clinical improvement. The patient's general condition got worse, swelling of the legs was pronounced, he had syncope. The patient was not motivated for hospitalization, and died.



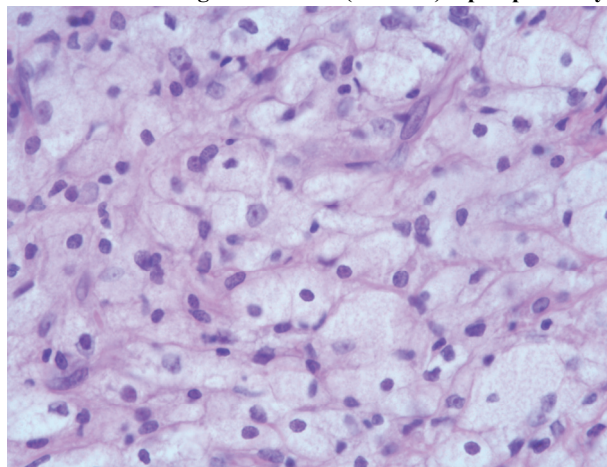
Fig. 1 – Bone scintigraphy – increased accumulation of radiopharmaceutical along the diaphysis of radius, ulna and humerus bilaterally, in the lower part of the left femur and along the left tibia.



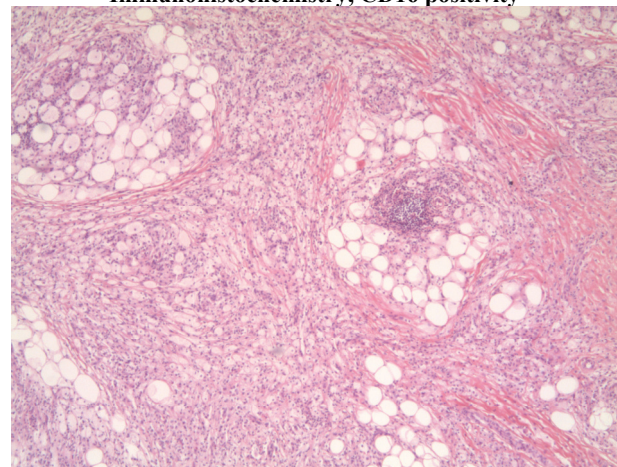
Platelet – derived growth factor (PDGFR) alpha positivity



Immunohistochemistry, CD16 positivity



Hematoxylin – eosin (HE, × 20)



Hematoxylin – eosin (HE, × 5)

Fig. 2 – Patohistological findings

Discussion

ECD is a rare disease. Considering different clinical features and disease activity, varying from asymptomatic to fulminant organ failure, the diagnosis is usually delayed. Patients without cardiac and pulmonary involvement have longer life expectancy. Intraperitoneal localization of ECD is very rare. That is exactly what we want to emphasize with this case report – the diagnosis is delayed, almost every organ can be affected, intraperitoneal localisation is very rare, there are no established guidelines for treatment. Regarding the abdominal form, the most affected is the retroperitoneum³³. There are only few cases of ECD with intraperitoneal involvement published^{16–19}, one case describes histiocytes in ascites fluid¹⁵. The gastrointestinal tract is rarely affected^{20, 21}. Only one case published in the literature describes mucosal findings with histiocyte infiltration found on histology – nodular gastritis of the entire stomach and small hyperpigmented lesions on colonic mucosa²².

Treatment regimen depends on the localization of the disease. Cytotoxic therapy is commonly used, but interferon alpha 2A, 3–9 million units 3 times *per* week, is considered as the first-line therapy²³. The mechanism of action of interferon alpha 2A in ECD is not fully understood: it influences

maturing and activation of dendritic cells, activates the natural killer cells which leads to the destruction of histiocyte and acts cytotoxicly directly to histiocyte²³.

As salvage therapy in six patients with severe multisystemic ECD, refractory to other therapies, and histiocytes positive to PDGFR beta, Haroche et al.²⁴ used imatinib mesylate, 100–800 mg once a day. Autologous hematopoietic-stem cell transplantation in a young patient, after disease progression following a few lines of therapy, has also been described²⁵. In case of bone involvement, zoledronic acid showed promising results²⁶. Mammalian target of rapamycin (mTOR) could be a new target in ECD. Gianfreda et al.²⁹ treated 10 patients with prednison and sirolimus, and achieved stable disease in 8 patients. Tumor necrosis factor alpha (TNF α) is a key regulator of inflammation in ECD. Infliximab was safely used in treating two patients, with clinical improvement³⁰. BRAF inhibitor vemurafenib could be used to treat patients with BRAF mutation³¹. Recent data suggest that canakinumab is a potential new drug for ECD³². Systematic review of 448 patients, published recently, provides detailed clinical features, prognostic and predictive factors. INF α based therapy is a reliable option, but a new therapy is emerging: infliximab, BRAF inhibitors, and mTOR inhibitors³³.

We described a case with the multisystemic form of ECD, affecting long bones, the hypophysis, abdominal cavity, and peripheral nerves. The disease presented with diabetes *insipidus*, then manifested as soft-tissue tumor of the right lower extremity. It was probably histiocytoma, unrecognized histopathologically. Xanthogranulomatous inflammation of fat tissue of the omentum was confirmed with laparoscopic biopsy, while the diagnosis of ECD was made based on clinical features, pathological/immunohistochemical findings and radiological criteria. The differential diagnosis included: Langerhans cell histiocytosis, Rosai-Dorfman disease, multiple myeloma, Whipple's disease, hemophagocytic syndromes. Taking into consideration that the patient was not motivated for chemotherapy, treatment included: prednisone, interferon alpha 2A, imatinib mesylate. Due to disease

progression the patient died, nine years after the initial symptoms (five years after the diagnosis was made).

Conclusion

ECD is a rare form of a non-Langerhans-cell histiocytosis of unknown etiology. It affects elderly, usually is unrecognized in the beginning. It is mainly multisystemic, thus it is necessary to start therapy as soon as possible. The prognosis depends on the extraskelatal manifestations of the disease, especially cardiac and pulmonary involvement. There are no guidelines for treatment of ECD. Interferon alpha is thought to be the first-line therapy. New therapy appears on horizon: infliximab, BRAF inhibitors, mTOR inhibitors.

REFERENCES

1. *Chester W.* Über lipoid Granulomatose. *Virchows Arch Pathol Anat* 1930; 279(2): 561–602.
2. *Cavalli G, Biavasco R, Borgiani B, Dagna L.* Oncogene-induced senescence as a new mechanism of disease: The paradigm of erdheim-chester disease. *Front Immunol.* 2014; 5: 281.
3. *Emile J, Diamond EL, Hélias-Rodzewicz Z, Cohen-Aubart F, Charlotte F, Hyman DM, et al.* Recurrent RAS and PIK3CA mutations in Erdheim-Chester disease. *Blood* 2014; 124(19): 3016–9.
4. *Bosco J, Allende A, Varikatt W, Lee R, Stewart GJ.* Does the BRAF(V600E) mutation herald a new treatment era for Erdheim-Chester disease? A case-based review of a rare and difficult to diagnose disorder. *Intern Med J* 2015; 45(3): 348–51.
5. *Antunes C, Graça B, Donato P.* Thoracic, abdominal and musculoskeletal involvement in Erdheim-Chester disease: CT, MR and PET imaging findings. *Insights Imaging* 2014; 5(4): 473–82.
6. *Veysier-Belot C, Cacoub P, Caparrós-Lefebvre D, Wechsler J, Brun B, Remy M, et al.* Erdheim-Chester disease. Clinical and radiologic characteristics of 59 cases. *Medicine (Baltimore)* 1996; 75(3): 157–69.
7. *Bourke SC, Nicholson AG, Gibson GJ.* Erdheim-Chester disease: Pulmonary infiltration responding to cyclophosphamide and prednisolone. *Thorax* 2003; 58(11): 1004–5.
8. *Yano S, Kobayashi K, Kato K, Tokuda Y, Ikeda T, Takeyama H.* A case of Erdheim-Chester disease effectively treated by cyclophosphamide and prednisolone. *Nihon Kogyaku Gakkai Zasshi* 2007; 45(1): 43–8.
9. *Ho P, Smith C.* High-dose methotrexate for the treatment of relapsed central nervous system erdheim-chester disease. *Case Rep Hematol* 2014; 2014: 269359.
10. *Darstein F, Kirschev S, Heckl S, Rahman F, Schwarting A, Schuchmann M, et al.* Successful treatment of Erdheim-Chester disease with combination of interleukin-1-targeting drugs and high-dose glucocorticoids. *Intern Med J* 2014; 44(1): 90–2.
11. *Myra C, Sloper L, Tighe PJ, McIntosh RS, Stevens SE, Gregson RH, et al.* Treatment of Erdheim-Chester disease with cladribine: A rational approach. *Br J Ophthalmol* 2004; 88(6): 844–7.
12. *Adam Z, Sprláková A, Reháček Z, Koukalová R, Štúrčík P, Krejčí M, et al.* Partial regression of CNS lesions of Erdheim-Chester disease after treatment with 2-chlorodeoxyadenosine and their full remission following treatment with lenalidomide. *Klin Onkol* 2011; 24(5): 367–81.(Czeck)
13. *Broccoli A, Stefoni V, Faccioli L, Agostinelli C, Spinardi L, Pastore TM, et al.* Bilateral orbital Erdheim-Chester disease treated with 12 weekly administrations of VNCOP-B chemotherapy: A case report and a review of literature. *Rheumatol Int* 2012; 32(7): 2209–13.
14. *Haroche J, Amoura Z, Trad SG, Wechsler B, Cluzel P, Grenier PA, et al.* Variability in the efficacy of interferon-alpha in Erdheim-Chester disease by patient and site of involvement: Results in eight patients. *Arthritis Rheum* 2006; 54(10): 3330–6.
15. *Ota M, Sakamoto M, Sato K, Yoshida Y, Funakubo AY, Akijama Y, et al.* Immunopathological analysis of Erdheim-Chester disease with massive ascites. *Intern Med* 2012; 51(19): 2825–30.
16. *Gupta A, Aman K, Al-Babtain M, Al-Wazgan H, Moronf R.* Multisystem Erdheim-Chester disease; a unique presentation with liver and axial skeletal involvement. *Br J Haematol* 2007; 138(3): 280.
17. *Pan A, Doyle T, Schlup M, Lubcke R, Schultz M.* Unusual manifestation of Erdheim-Chester disease. *BMC Gastroenterol* 2011; 11: 77.
18. *Gundling F, Nerlich A, Heitland W, Schepp W.* Biliary manifestation of Erdheim-Chester disease mimicking Klatskin's carcinoma. *Am J Gastroenterol* 2007; 102(2): 452–4.
19. *Ivan D, Neto A, Lemos L, Gupta A.* Erdheim-Chester disease: A unique presentation with liver involvement and vertebral osteolytic lesions. *Arch Pathol Lab Med* 2003; 127(8): e337–9.
20. *Tevlin R, Cabalane AM, Larkin JO, Treacy A, Connaghan D, Winter DC.* Gastrointestinal Erdheim-Chester disease. *Ir Med J* 2014; 107(5): 149–50.
21. *Vermeiren P, Van Laecke S, Cavelier C, De Loose D, Vanholder R.* Progressive dysphagia caused by Erdheim-Chester disease. *QJM* 2014; 107(12): 1015–7.
22. *Ben-Yaakov G, Munteanu D, Sztarkier I, Fich A, Schwartz D.* Erdheim Chester: A rare disease with unique endoscopic features. *World J Gastroenterol* 2014; 20(25): 8309–11.
23. *Haroche J, Amoura Z, Trad SG, Wechsler B, Cluzel P, Grenier PA, et al.* Variability in the efficacy of interferon-alpha in Erdheim-Chester disease by patient and site of involvement: result in eight patient. *Arthritis Rheum* 2006; 54(10): 3330–6.
24. *Haroche J, Amoura Z, Charlotte F, Salvatierra J, Wechsler B, Graux C, et al.* Imatinib mesylate for platelet-derived growth factor receptor-beta-positive Erdheim-Chester histiocytosis. *Blood* 2008; 111(11): 5413–5.
25. *Boissel N, Wechsler B, Leblond V.* Treatment of refractory Erdheim-Chester disease with double autologous hematopoietic stem-cell transplantation. *Ann Intern Med* 2001; 135(9): 844–5.
26. *Srikulmontree T, Massey DH, Roberts NW.* Treatment of skeletal Erdheim-Chester disease with zoledronic acid: Case report and proposed mechanisms of action. *Rheumatol Int* 2007; 27(3): 303–7.

27. *Aouba A, Georgin-Lavialle S, Pagnoux C, Martin SN, Renand A, Galateau-Salle F, et al.* Rationale and efficacy of interleukin-1 targeting in Erdheim-Chester disease. *Blood* 2010; 116(20): 4070–6.
28. *Miller RC, Villà S, Kamer S, Pasquier D, Poortmans P, Mücke O, et al.* Palliative treatment of Erdheim-Chester disease with radiotherapy: A Rare Cancer Network study. *Radiother Oncol* 2006; 80(3): 323–6.
29. *Gianfreda D, Nicastro M, Galetti M, Alberici F, Corradi D, Becchi G, et al.* Sirolimus plus prednisone for Erdheim-Chester disease: An open-label trial. *Blood* 2015; 126(10): 1163–71.
30. *Dagna L, Corti A, Langheim S, Guglielmi B, De Cobelli F, Doglioni C, et al.* Tumor necrosis factor α as a master regulator of inflammation in Erdheim-Chester disease: Rationale for the treatment of patients with infliximab. *J Clin Oncol* 2012; 30(28): e286–90.
31. *Tzoulis C, Schwarzmüller T, Gjerde IO, Søfteland E, Neckelmann G, Biermann M, et al.* Excellent response of intramedullary Erdheim-Chester disease to vemurafenib: A case report. *BMC Res Notes* 2015, 8: 171.
32. *Tran T, Pariente D, Guittou C, Delwail A, Barat-Houari M, Meinzger U.* Treatment of Erdheim-Chester disease with canakinumab. *Rheumatology (Oxford)* 2014; 53(12): 2312–4.
33. *Cives M, Simone V, Rizzò FM, Dicuonzo F, Cristallo Lacalamita M, Ingravallo G, et al.* Erdheim-Chester disease: A systematic review. *Crit Rev Oncol Hematol* 2015; 95(1): 1–11.

Received on October 12, 2015.

Revised on November 17, 2015.

Accepted on November 20, 2015.

Online First May, 2016.